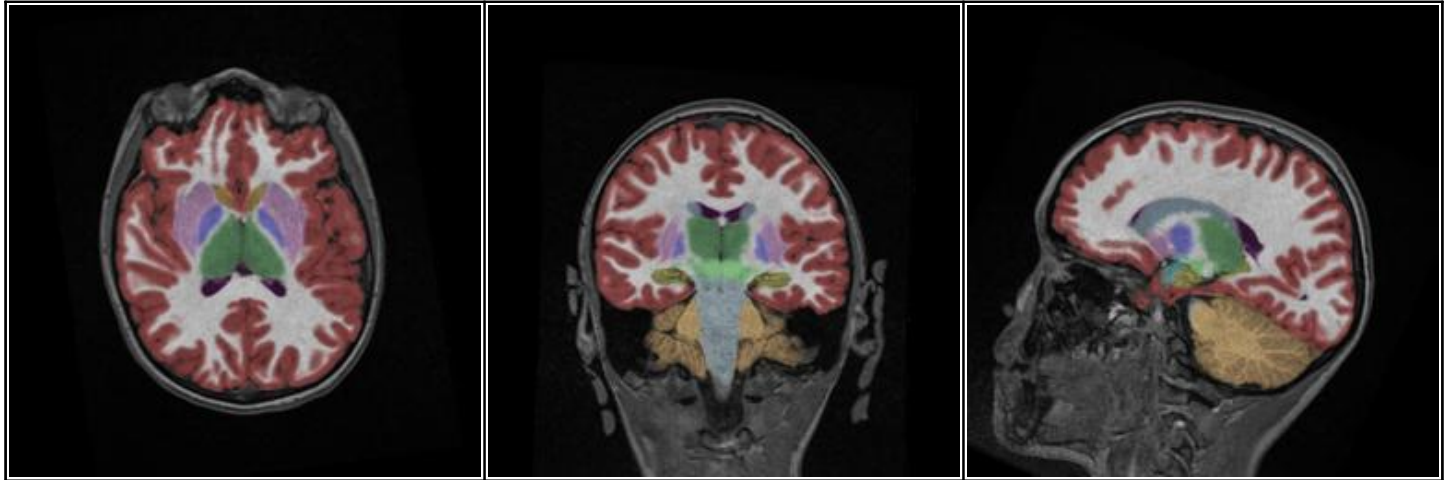


PATIENT INFORMATION

Version 2.3.0

Patient ID:	Patient Name:	Sex: F	Age: 6
Accession Number:	Referring Physician:	Exam Date:	

MORPHOMETRY RESULTS



Brain Structure	Volume (cm ³)	% of ICV (5%-95% Normative Percentile)	Normative Percentile
Intracranial Volume (ICV)	1833.53	N/A	55
Forebrain Parenchyma	1347.20	73.48 (66.98 - 74.58)	86
Superior Lateral Ventricles	13.28	0.72 (0.11 - 1.31)	72

AGE-MATCHED REFERENCE CHARTS

